



Articles

2015-06-01

Lower Macular Pigment Optical Density in Foveal-Involved Glaucoma.

James Loughman

Technological University Dublin, james.loughman@dit.ie

Follow this and additional works at: <https://arrow.dit.ie/otpomart>

 Part of the [Ophthalmology Commons](#)

Recommended Citation

Siah WF. et al (2015) Lower Macular Pigment Optical Density in Foveal-Involved Glaucoma. *Ophthalmology*, 2015 Aug 3. pii: S0161-6420(15)00616-8. doi: 10.21427/nhxe-aa69

This Article is brought to you for free and open access by ARROW@TU Dublin. It has been accepted for inclusion in Articles by an authorized administrator of ARROW@TU Dublin. For more information, please contact yvonne.desmond@dit.ie, arrow.admin@dit.ie, brian.widdis@dit.ie.



This work is licensed under a [Creative Commons Attribution-Noncommercial-Share Alike 3.0 License](#)



Lower Macular Pigment Optical Density in Foveal-Involved Glaucoma

We Fong Siah, MRCPI, FRCOphth,¹ James Loughman, FAOI, PhD,^{2,3} Colm O'Brien, FRCOphth, MD¹

Purpose: To evaluate the relationship between macular pigment optical density (MPOD) and structural parameters of the macula and optic nerve head in glaucomatous eyes.

Design: A cross-sectional analysis of the baseline data collected during the Macular Pigment and Glaucoma Trial (ISRCTN registry number: 56985060).

Participants: Eighty-eight subjects (48 male, 40 female) with a diagnosis of open-angle glaucoma and a median age of 67 years (interquartile range, 13; range, 36–84 years) were enrolled in this trial.

Methods: The MPOD at 0.25°, 0.5°, and 1° retinal eccentricity was measured using a customized heterochromatic flicker photometry technique. Glaucoma-related structural parameters were captured using RTVue Fourier-domain optical coherence tomography (FD-OCT). Statistical significance was set at $P < 0.01$, and P values ranging from 0.01 to 0.05 were considered borderline significant.

Main Outcome Measures: The MPOD and its relationship to the macula and optic nerve head topography in glaucomatous eyes.

Results: The MPOD peaked centrally at 0.25° of retinal eccentricity (mean \pm standard deviation, 0.23 \pm 0.14) and decreased at more peripheral eccentricities. For the overall group, borderline significant correlations were observed between MPOD and a range of topographic measures, including inferior peripapillary retinal nerve fiber layer (RNFL) thickness, inferior ganglion cell complex (GCC) thickness, foveal inner retinal thickness, cup-to-disc area ratio, and optic disc rim area. Glaucomatous eyes with GCC loss involving the foveal zone on FD-OCT imaging ($n = 52$) had lower MPOD at 0.25°, 0.5°, and 1° of retinal eccentricity compared with those without foveal GCC involvement ($P < 0.001$, for all). Those with foveal GCC loss also had greater glaucoma severity, and this was evident by lower GCC and RNFL thickness, greater cup-to-disc area ratio, and lower optic disc rim area ($P < 0.001$ for all).

Conclusions: Our observations indicate that MPOD is lower in glaucomatous eyes with foveal GCC involvement relative to those without foveal involvement. A longitudinal evaluation of MPOD and structural change among patients with glaucoma is required to elucidate the nature of any causal relationship that might exist between MPOD and foveal damage in glaucoma. *Ophthalmology* 2015;■:1–9 © 2015 by the American Academy of Ophthalmology.

The macula can be involved in the early stage of glaucoma, as evidenced by the presence of paracentral scotoma on visual field tests¹ or thinning of the ganglion cell complex (GCC) layer on optical coherence tomography (OCT) scans.² In the human retina, the ganglion cells are most densely located at the macula, and approximately 50% are concentrated within 4.5 mm of the fovea.³ Macular pigment (MP), which comprises the hydroxycarotenoids lutein, zeaxanthin, and meso-zeaxanthin, is also known to be most densely concentrated around the fovea.⁴ Both lutein and zeaxanthin are solely of dietary origin, whereas meso-zeaxanthin can be synthesized de novo from retinal lutein.⁵

Macular pigment is believed to possess the following properties: (1) acts as a potent antioxidant,⁶ (2) exhibits preferential spectral absorption of short-wavelength light,⁷ and (3) benefits visual performance.⁸ Macular pigment optical density (MPOD) in individual eyes can be measured using a variety of techniques, including heterochromatic flicker photometry (HFP).⁹ The protective effect of MP has

been demonstrated in age-related macular degeneration (AMD), a retinal neurodegenerative disorder in which old age and oxidative stress have been implicated.¹⁰ It has been shown that oral dietary MP supplementation can augment MPOD and improve visual function in individuals with AMD¹¹ and those without underlying ocular disease.¹²

Glaucoma is also associated with the aging eye, and oxidative stress is known to play a vital role in its pathogenesis.¹³ The possible role of oxidative stress in glaucoma, coupled with emerging evidence that (1) the structural integrity of the macula is affected early in glaucoma and (2) MP levels may be compromised in glaucoma¹⁴ was sufficient to prompt this investigation into the relationship between MP and structural aspects of glaucoma in the macular region. To our knowledge, this is the first time the relationship between MPOD and glaucoma-related topography has been investigated. Given the fact that MP is largely concentrated to the central 1° of retinal eccentricity of the macula, we were keen to

explore glaucoma involving the foveal zone using OCT imaging. Currently, the potential benefit of dietary MP supplementation in glaucoma is yet to be elucidated.

Methods

Subjects

The Macular Pigment and Glaucoma Trial is a prospective, placebo-controlled, double-masked randomized study (ISRCTN registry number: 56985060). This article comprises an analysis of the baseline MP and structural data collected during this trial. Eighty-eight subjects with a diagnosis of open-angle glaucoma were recruited into this study, which has been approved by the Research Ethics Committees at the Mater Misericordiae University Hospital, Dublin, and the Dublin Institute of Technology. Written informed consent was obtained from all subjects, and the study adhered to the tenets of the Declaration of Helsinki.

Open-angle glaucoma was defined as the presence of glaucomatous optic disc cupping with associated visual field loss in an eye with a gonioscopically open anterior chamber drainage angle. The different open-angle glaucoma subtypes that were considered for inclusion were (a) primary open-angle glaucoma (POAG) (intraocular pressure >21 mmHg); (b) normal-tension glaucoma (NTG) (intraocular pressure ≤ 21 mmHg); (c) pseudoexfoliative glaucoma (fibrillar deposits in the anterior segment of the eye); and (d) pigment dispersion glaucoma (peripheral iris transillumination and pigment deposition throughout the anterior segment structures of the eye). Other inclusion criteria were age >18 years and subject capacity to adhere to trial protocol. Exclusion criteria included an Early Treatment Diabetic Retinopathy Study (ETDRS) logarithm of the minimum angle of resolution (logMAR) visual acuity >0.30 , underlying ocular pathology such as AMD or moderate to significant cataract (using Lens Opacity Classification System III grading), previous ocular surgery other than for cataract extraction or glaucoma drainage procedure, coexisting blue-light filter intraocular lens, history of diabetes mellitus, or the use of an oral dietary macular pigment supplement within the past 6 months. All subjects had characteristic and reproducible glaucomatous field defects on standard automated perimetry (Humphrey Visual Field [HVF] Analyzer 24-2 Swedish Interactive Threshold Algorithm Fast program; Carl Zeiss Meditec, Jena, Germany).

Demographic information, including age, gender, type of glaucoma, years diagnosed with glaucoma, history of smoking (current smoker, ex-smoker, and never smoked), and body mass index (kilograms per meters squared) were recorded for each subject. Throughout the study, only 1 eye per subject was selected for testing. If both eyes were eligible, the study eye was randomly selected using the randomization software Research Randomizer (version 4.0). All glaucoma subjects underwent a comprehensive eye examination including ETDRS logMAR visual acuity, slit-lamp biomicroscopy, MPOD measurement (HFP), RTVue (software version 5.1; Optovue Inc., Fremont, CA), Fourier-domain optical coherence tomography (FD-OCT) imaging of the optic nerve head and macula, and standard automated perimetry. The logMAR test chart used was computer generated (version 1.1; KyberVision, Quebec, Canada), and visual acuity was tested at a viewing distance of 4 m, using a Sloan ETDRS letter set, while wearing current distance spectacle prescription where required.

Measurement of Macular Pigment Optical Density

Heterochromatic flicker photometry is a psychophysical technique for measuring MPOD that has been validated against the

absorption spectrum of MP *in vitro*.¹⁵ It has also been shown to provide reliable data when compared with other methods of measuring MPOD, such as fundus reflectometry and fluorophotometry.^{16,17} Because the HFP technique is not dependent on or affected by regional variation in sensitivity at the central and peripheral retinal loci (normal or disease-induced variations),¹⁶ the HFP technique remains appropriate for MPOD measurement among glaucoma subjects. In this study, MPOD was measured using the Macular Densitometer (Macular Metrics, Rehoboth, MA), a device originally described by Wooten and colleagues.¹⁶ Subjects viewed a stimulus consisting of a square wave, alternating blue (460 nm) and green (550 nm), flickering light-emitting diode light source. Subjects were required to make iso-luminance matches, which were perceived as the point of cessation of flicker (null flicker). All subjects were shown a training video before being tested with the densitometer and were afforded the opportunity to practice the technique. A customized HFP approach was used, a refined technique that allowed the investigator to predetermine the optimal flicker frequency for each subject, thus enabling a more discrete end point for the test and minimizing the variance between readings.¹⁸ In this study, the spatial profile of MP at 0.25° , 0.5° , and 1° of retinal eccentricity was measured under conditions of dimmed light at a viewing distance of 18.5 inches (47 cm), with distance optical correction where required. Five readings were obtained to produce a mean MPOD value at each retinal eccentricity, which was deemed reliable and acceptable for inclusion in the study when the standard deviation of measures was 0.05 or less.

Fourier-Domain Optical Coherence Tomography

All subjects were scanned using the RTVue FD-OCT system, with a scan speed of 26 000 A-scans/second and 5- μ m axial resolution. The protocols used included (a) the retinal nerve fiber layer (RNFL) 3.45 scan; (b) the optic nerve head scan; (c) the Enhanced Macular Map 5 (EMM5) scan; and (d) the GCC scan.

The RNFL 3.45 protocol acquired four 3.45-mm-diameter circular scans centered on the optic disc and provided the average RNFL thickness at the temporal, superior, nasal, and inferior quadrants (peripapillary RNFL). The optic nerve head scan pattern consisted of 12 radial line scans of 3.4-mm length and 13 concentric rings (1.3- to 4.9-mm diameter) centered on the optic disc, providing a detailed optic disc/rim/cup analysis. The EMM5 scan pattern captured 29 438 data points across the macula over 0.90 seconds and provided information such as the full retinal and inner retinal thickness at the fovea, parafoveal, and perifoveal regions, which are 1 ($\sim 3.3^\circ$), 3, and 5 mm in diameter, respectively.

The MP is localized within the foveal and parafoveal regions, and therefore these regions were a priority focus in this study. The EMM5 scan image was excluded from analysis in the presence of a poor-quality image (signal strength <40), segmentation error, off-center fixation, or out-of-range image.¹⁹ The GCC scan pattern specifically provided a comprehensive ganglion cell assessment by measuring the thickness of the nerve fiber layer (ganglion cell axons), ganglion cell layer (ganglion cell body), and inner plexiform layer (ganglion cell dendrites) at the macula. The macular region was scanned over 0.58 seconds and consists of 1 horizontal line and 15 vertical lines at 0.5-mm intervals. The scan was centered 1 mm temporal to the fovea to produce a 7-mm² region. The RTVue software cropped the outer 0.5-mm region to provide a 6-mm GCC thickness map that was used for the calculation of the GCC Significance Map. This 6 \times 6-mm map spans an area that is equivalent to the central 20° on a visual field map. If the signal strength index was poor at <40 or the scan was misaligned, the images were not used.

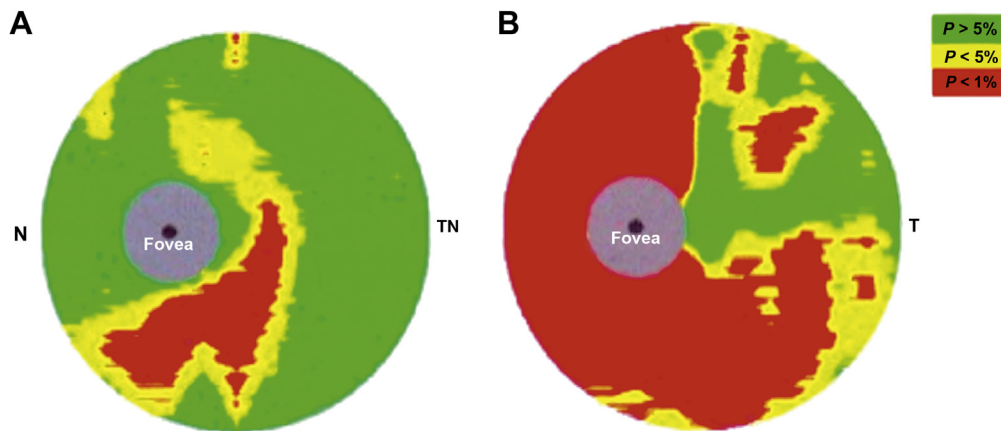


Figure 1. Ganglion cell complex (GCC) significance map. A, Fovea-not-involved. B, Fovea-involved. N = nasal; T = temporal.

Ganglion Cell Complex Subgroups

In the GCC color-coded Significance Map, the central, grey foveal area (1.5 mm/5° diameter) covers the region where the GCC thickness is too thin to be evaluated. In a normal eye, the MP is most densely located within the diameter of this grey area. Beyond approximately 7° eccentricity, retinal MP becomes optically undetectable.²⁰ Glaucoma subjects were divided into 2 subgroups based on their GCC Significance Map to better represent the GCC thickness in relation to the anatomic location of the MP. All diagnostic parameters in the GCC Significance Map were color coded to indicate whether there was any significant GCC thickness reduction; $P < 1\%$ was coded as red, $P < 5\%$ was coded as yellow, and $P \geq 5\%$ was coded as green. If the perimeter of the grey foveal area was green, it was classified as “fovea-not-involved” (Fig 1A). If the red scale encroached up to the grey area, it was classified as “fovea-involved” (Fig 1B). A general linear model analysis was used to determine the effect of foveal involvement (“fovea-not-involved” vs. “fovea-involved” subgroups) and age, years diagnosed with glaucoma, smoking status, and body mass index on the dependent variable, MPOD.

Dietary Intake of Lutein and Zeaxanthin

A self-administered, semiquantitative food frequency questionnaire (Lutein Zeaxanthin Questionnaire) was used to assess the dietary intake of lutein and zeaxanthin (Carotenoid & Health Laboratory, Jean Mayer USDA Human Nutrition Center on Aging, Tufts University, Medford, MA),²¹ as has been used in other MPOD studies.²² This information allowed us to control for any MPOD disparity that may arise from different dietary habits among the glaucoma subjects.

Statistical Analysis

Results were analyzed using the statistical software package SPSS (version 22.0; IBM Corp., New York, NY). The Kolmogorov–Smirnov test (if $n > 50$) or Shapiro–Wilk W test (if $n \leq 50$) was used to assess the normality of all variables before statistical analysis. Most of the quantitative variables that were investigated exhibited a normal distribution except for age, duration of glaucoma diagnosis, body mass index, peripapillary RNFL thickness, superior macular RNFL thickness, cup-to-disc ratio, and optic disc rim area. Various statistical analyses including an independent t test, Mann–Whitney U test, analysis of variance (ANOVA) with post hoc tests, and Pearson or Spearman correlation coefficients were computed when

appropriate. A conservative 1% level of significance was adopted throughout the analysis to offset the risk of a type I error given the multiple comparisons and correlations conducted, although the majority of statistical tests were unrelated. The GCC thickness subgroup analyses (“fovea-not-involved” and “fovea-involved”) were performed to explore relationships, if any, with other glaucoma-related OCT parameters and MPOD.

Results

Demographics

The demographics for all 88 glaucoma subjects are summarized in Table 1. The right eye was selected for inclusion in 51 subjects (58%), and the left eye was selected for the remaining 37 subjects (42%).

Macular Pigment Optical Density

Valid MPOD data were obtained for 69 subjects at 0.25° retinal eccentricity (mean \pm standard deviation, 0.23 \pm 0.14), 81 subjects at 0.5° eccentricity (0.19 \pm 0.12), and 59 subjects at 1° eccentricity (0.12 \pm 0.09). Only 53 subjects had complete MPOD data at all 3 retinal eccentricities. Of these subjects, 46 displayed a typical MP spatial profile with a central peak at 0.25° and relative decline at more peripheral eccentricities, whereas the remaining 7 subjects exhibited atypical MP spatial profiles that peaked at 0.5° of retinal eccentricity.

There was no statistically significant correlation observed between MPOD and age ($r = -0.21$, $P = 0.08$ at 0.25° eccentricity; $r = -0.23$, $P = 0.04$ at 0.5° eccentricity; $r = -0.17$, $P = 0.19$ at 1° eccentricity) or length of time since being diagnosed with glaucoma ($r = -0.24$, $P = 0.05$ at 0.25° eccentricity; $r = -0.09$, $P = 0.44$ at 0.5° eccentricity; $r = -0.11$, $P = 0.40$ at 1° eccentricity), although there was a trend toward significance ($P = 0.01$ – 0.05) in both instances at some eccentricities. Likewise, no statistically significant correlation was observed between MPOD and body mass index at any eccentricity ($r = -0.13$, $P = 0.28$ at 0.25° eccentricity; $r = 0.01$, $P = 0.93$ at 0.5° eccentricity; $r = -0.08$, $P = 0.57$ at 1° eccentricity). Independent t test analysis showed no gender-based difference in MPOD ($P > 0.01$ for all). One-way ANOVA revealed no statistically significant effect of smoking habits (current smoker, ex-smoker, and never smoked) on MPOD. Although there was no statistically significant correlation between MPOD and OCT structural parameters at the strict 0.01 threshold, borderline significant ($P = 0.01$ – 0.05) correlations were observed

Table 1. Subject Characteristics (N = 88)

Characteristic	Result
Age (yrs), median (range)	67 (36–84)
Sex, n (%)	
Male	48 (54.5)
Female	40 (45.5)
Study eye logMAR, mean ± SD	0.03±0.10
Type of glaucoma, n (%)	
POAG	45 (51.1)
NTG	31 (35.2)
PXG	9 (10.2)
PDG	3 (3.4)
Duration of glaucoma (yrs), median (range)	6 (0.5–32)
Smoking habits, n (%)	
Never smoked	42 (47.7)
Ex-smoker	36 (40.9)
Current smoker	10 (11.4)
Body mass index (kg/m ²), median (range)	25.5 (18.5–42)
Lutein intake (mg/dl), median (range)	0.7 (0–13.2)
Zeaxanthin intake (mg/dl), median (range)	0.1 (0–1.2)

LogMAR = logarithm of the minimum angle of resolution; NTG = normal-tension glaucoma; PDG = pigment dispersion glaucoma; POAG = primary open-angle glaucoma; PXG = pseudoexfoliative glaucoma; SD = standard deviation.

between MPOD and a number of topographic measures, including inferior peripapillary RNFL thickness, inferior GCC thickness, inner retinal thickness at the fovea, cup-to-disc area ratio, and optic disc rim area (Table 2).

Optical Coherence Tomography Parameters and Ganglion Cell Complex Subgroups

Of the 88 GCC scans completed, 3 demonstrated poor signal strength and were eliminated from the analysis. In total, there were 33 subjects (38.8%) in the “fovea-not-involved” subgroup and 52 subjects (61.2%) in the “fovea-involved” subgroup.

Figure 2 shows the difference in MPOD spatial profile between the “fovea-not-involved” and “fovea-involved” subgroups. Table 3 shows the different types of glaucoma within the GCC subgroups and other characteristics. The 2 most common types of glaucoma within the “fovea-involved” group were POAG (n = 22) and NTG (n = 23). Between these subgroups, no significant differences in MPOD or any OCT parameters were observed ($P > 0.01$ for all).

Within GCC subgroups, no statistically significant correlation was observed between MPOD (at 0.25°, 0.5°, and 1° retinal eccentricities, respectively) and age, length of time since diagnosed with glaucoma, and body mass index ($P > 0.01$ for all). There was no significant gender-based difference in MPOD at all retinal eccentricities within the GCC subgroups ($P > 0.01$ for all, independent *t* test). Furthermore, 1-way ANOVA did not reveal any significant effect of smoking habits on MPOD in either subgroup ($P > 0.01$ for each).

A statistically significant difference in MPOD between the “fovea-not-involved” and “fovea-involved” GCC subgroups was observed at all retinal eccentricities ($P < 0.001$ for all) (Table 4). Furthermore, the “fovea-involved” group exhibited more severe glaucoma as determined by thinner RNFL and GCC, larger cup-to-disc area ratio, and a smaller optic disc rim area ($P < 0.01$ for each). However, MPOD did not correlate significantly with OCT structural parameters for the “fovea-not-involved” or “fovea-involved” GCC subgroup ($P > 0.01$

for all). A general linear model analysis confirmed a significant effect of foveal involvement (“fovea-not-involved” vs. “fovea-involved” subgroups) on MPOD at all retinal eccentricities ($P \leq 0.001$), but no effect of age, years diagnosed with glaucoma, smoking status, and body mass index on MPOD ($P = 0.12$ – 0.72 at 0.25° retinal eccentricity, $P = 0.34$ – 0.99 at 0.5° retinal eccentricity, $P = 0.49$ – 0.88 at 1° retinal eccentricity).

Median lutein intake in the “fovea-not-involved” group was 0.7 mg/dl (range, 0–13.2 mg/dl), whereas that in the “fovea-involved” group was 0.8 mg/dl (range, 0–13.1 mg/dl). These respective intakes were not statistically significantly different ($P = 0.95$, Mann–Whitney *U* test). Likewise, we did not find any significant difference in zeaxanthin intake between the “fovea-not-involved” group (median, 0.1 mg/dl; range, 0–0.5 mg/dl) and the “fovea-involved” group (median, 0.1 mg/dl, range, 0–1.2 mg/dl) ($P = 0.44$, Mann–Whitney *U* test).

Discussion

Macular pigment has been shown to be lower among subjects with glaucoma compared with healthy controls.¹⁴ This study extends those findings and suggests that a continuum exists, whereby MPOD not only is lower in the presence of glaucoma but also is further compromised in more severe cases of the condition and, in particular, where foveal ganglion cells are involved. We also found borderline significant correlations between MPOD in the overall group and OCT-derived topography measures, which may further imply a relationship between MP and glaucoma-related structural parameters.

Table 2. Relationship between Macular Pigment Optical Density and Optical Coherence Tomography Parameters

	MPOD 0.25°		MPOD 0.5°		MPOD 1°	
	R*	P	R*	P	R*	P
Peripapillary RNFL thickness						
Average	0.15 [†]	0.23	0.16 [†]	0.18	0.07 [†]	0.60
Superior	0.13 [†]	0.31	0.12 [†]	0.30	0.02 [†]	0.89
Inferior	0.21 [†]	0.09	0.23 [†]	0.05	0.15 [†]	0.28
Macular RNFL thickness						
Average	0.11	0.36	0.18	0.12	0.12	0.36
Superior	0.05 [†]	0.68	0.11 [†]	0.35	0.03 [†]	0.83
Inferior	0.18	0.14	0.21	0.07	0.16	0.22
GCC thickness						
Average	0.15	0.24	0.16	0.15	0.22	0.09
Superior	0.06	0.63	0.11	0.33	0.13	0.33
Inferior	0.21	0.09	0.18	0.11	0.27	0.04
Foveal thickness						
Full retina	0.09	0.52	0.18	0.15	0.18	0.22
Inner retina	0.19	0.17	0.29	0.02	0.23	0.11
Parafoveal thickness						
Full retina	0.03	0.85	0.09	0.46	0.07	0.66
Inner retina	0.16	0.24	0.20	0.11	0.14	0.35
Cup-to-disc-area ratio	–0.27 [†]	0.03	–0.25 [†]	0.03	–0.28 [†]	0.04
Optic disc rim area	0.28 [†]	0.02	0.22 [†]	0.06	0.22 [†]	0.10

GCC = ganglion cell complex; MPOD = macular pigment optical density; RNFL = retinal nerve fiber layer.

P = significance (2-tailed).

*Pearson coefficient correlation (unless indicated otherwise).

†Spearman coefficient correlation.

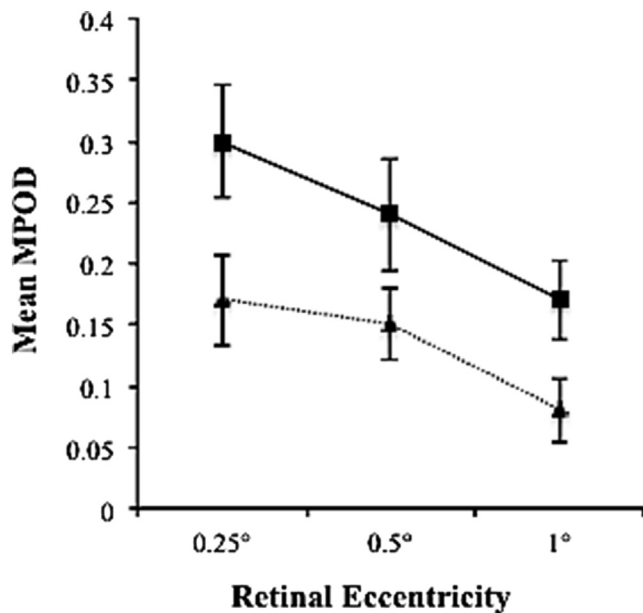


Figure 2. Mean macular pigment optical density (MPOD) spatial profile for subjects with glaucoma. —■—, Fovea-Not-Involved;▲....., Fovea-Involved.

In this study, only half of the patients with POAG had foveal involvement compared with a large proportion of those with NTG (77%). This finding was not surprising to us given that paracentral scotoma is a common finding in the early course of NTG. Pseudoexfoliative glaucoma is generally recognized as a more progressive glaucoma subtype. This may explain why the majority (78%) of patients in the pseudoexfoliative glaucoma group had foveal-involved glaucoma and displayed the worst glaucoma parameters (HVF 24-2 mean deviation [MD] and average GCC thickness, respectively) compared with other glaucoma subtypes.

Beatty et al²³ previously demonstrated the finding of an age-related decline in MPOD in individuals with healthy eyes, whereas an earlier study by Bone et al²⁰ showed the contrary. Given that glaucoma is a progressive retinal degenerative disease that tends to affect the aging individual, one could speculate that increasing age may, in part, be contributing to the decline in MPOD with advancing disease. Although subjects in the “fovea-involved” subgroup were older than in

the “fovea-not-involved” subgroup (mean age, 67.9 vs. 62.6 years, respectively), this difference was only borderline significant ($P = 0.02$, independent t test). However, our data are in keeping with the findings of Bone et al²⁰ and do not support the existence of a relationship between MPOD and age. Our earlier study (Igras et al¹⁴) showed that MPOD was significantly lower in glaucomatous eyes compared with age-matched controls. With our current data, it would seem that age is not a confounding factor, but the presence of foveal GCC loss is a major determinant of MPOD levels.

Adipose tissue acts as a major storage organ for carotenoids and therefore may compete with the retina for their uptake. It has been shown that an inverse relationship exists between MPOD and body mass index in those with healthy eyes.²⁴ In our study, we did not find any correlation between MPOD and body mass index.

In human eyes, the most central part of the fovea (also known as the foveal pit) measures 200 μm in diameter and is a region where only cone photoreceptors can be found.³ From here, the inner retinal structures are displaced radially to form the foveal slope, and eventually, at the parafovea (thickest portion of the retina), the ganglion cells are packed 6 layers thick. Macular pigment can be localized to the fibers of Henle and plexiform layers at the fovea and the inner and outer plexiform layers at the parafovea.⁴ This is of relevance because the 3 innermost retinal layers preferentially affected in glaucoma are (1) nerve fiber layer (ganglion cell axon), (2) ganglion cell layer (ganglion cell body), and (3) inner plexiform layer (ganglion cell dendrites).²⁵ Collectively, these 3 retinal layers constitute the GCC as measured by the RTVue FD-OCT.

Because of limitations of the RTVue FD-OCT to reliably evaluate GCC thickness at the fovea, we described a simple method to allow us to distinguish the presence or absence of foveal involvement in glaucoma subjects (see “Methods” section). The MPOD was significantly lower in subjects who exhibited evidence of GCC thinning that encroached on the foveal zone (“fovea-involved” GCC) relative to those without foveal GCC involvement. Given that the macular layers where MP is housed appear to be affected by glaucoma, this may explain, at least in part, the observation in this study that MPOD is lower in individuals with more severe glaucoma and, in particular, those with GCC loss at the fovea. However, our data in this study are not sufficient enough to make any conclusions on causal inferences.

Table 3. Types of Glaucoma and Characteristics

Types of Glaucoma	Fovea-Not-Involved (n = 33)			Fovea-Involved (n = 52)		
	n (%)	HVF 24-2 MD (dB)*	Mean GCC (μm)	n (%)	HVF 24-2 MD (dB)*	Mean GCC (μm)
POAG	22 (50)	-5.72 [†]	77.31	22 (50)	-10.41 [†]	70.11
NTG	7 (23)	-5.30	83.85	23 (77)	-8.79	71.47
PXG	2 (22)	-9.68	75.90	7 (78)	-16.24	68.66
PDG	2 (100)	-4.50	74.83	0 (0)	N/A	N/A

dB = decibels; GCC = ganglion cell complex; HVF = Humphrey Visual Field; MD = mean deviation; N/A = not applicable; NTG = normal-tension glaucoma; PDG = pigment dispersion glaucoma; POAG = primary open-angle glaucoma; PXG = pseudoexfoliative glaucoma.

*Mean (unless indicated otherwise).

[†]Median.

Table 4. Comparison between Ganglion Cell Complex Subgroups

	Fovea-Not-Involved	Fovea-Involved	P Value
MPOD, mean \pm SD			
0.25°	0.30 \pm 0.12	0.17 \pm 0.11	<0.001*
0.50°	0.24 \pm 0.12	0.15 \pm 0.10	<0.001*
1.00°	0.17 \pm 0.07	0.08 \pm 0.08	<0.001*
RNFL thickness (μ m), mean \pm SD			
Peripapillary	77.58 \pm 9.80	69.33 \pm 8.34	<0.001*
Macular	79.66 \pm 12.55	69.70 \pm 10.65	<0.001*
GCC thickness (μ m), mean \pm SD	78.46 \pm 7.71	70.38 \pm 9.34	<0.001*
Foveal thickness (μ m), mean \pm SD			
Full fovea	270.00 \pm 19.55	253.02 \pm 23.08	0.002*
Inner fovea	86.54 \pm 11.93	76.76 \pm 14.84	0.005*
Outer fovea	183.46 \pm 11.19	176.26 \pm 11.91	0.013*
Parafoveal thickness (μ m), mean \pm SD			
Full parafovea	306.03 \pm 20.06	285.45 \pm 18.99	<0.001*
Inner parafovea	119.06 \pm 12.25	106.20 \pm 9.42	<0.001*
Cup-to-disc area ratio, median (range)	0.76 (0.36–0.97)	0.88 (0.55–0.98)	<0.001†
Rim area (mm ²), median (range)	0.43 (0.06–0.86)	0.22 (0.05–0.71)	<0.001†
HVF 24-2 MD (dB), median (range)	-5.46 (-1.45 to -26.46)	-10.54 (-0.09 to -31.06)	0.018†

dB = decibels; GCC = ganglion cell complex; HVF = Humphrey visual field; MD = mean deviation; MPOD = macular pigment optical density; RNFL = retinal nerve fiber layer; SD = standard deviation.

*Two-tailed significance using the independent *t* test.

†Two-tailed significance using the Mann–Whitney *U* test.

In our earlier study, we showed that MPOD was significantly lower in glaucomatous eyes compared with controls.¹⁴ Also using the HFP technique, Igras et al¹⁴ showed that mean MPOD \pm standard deviation was 0.39 \pm 0.24 in a similar cohort of normal controls, in comparison with 0.19 \pm 0.12 at 0.5° of retinal eccentricity in this study. The current study was not designed to repeat that investigation, but rather to extend the study in an effort to better understand the relationship between MPOD and glaucoma-related structural parameters. As such, the lack of a normal control group is not a substantial limitation to the current study.

Igras et al¹⁴ also reported that MPOD did not correlate with glaucoma severity (HVF 24-2 MD), whereas the present study demonstrated a borderline significant ($P = 0.01$ – 0.05) correlation between MPOD and glaucoma-related structural parameters as measured by RTVue FD-OCT in the overall group. Furthermore, we also found that those with foveal-involved glaucoma had more severe disease (OCT parameters, $P < 0.01$; HVF 24-2 MD, $P = 0.02$) and demonstrated lower MPOD ($P < 0.001$) compared with those without foveal involvement. This disparity between the 2 studies likely reflects limitations in our earlier study, which had a smaller sample size (and therefore lacked statistical power), and where, importantly, a central visual field test (HVF 10-2) and OCT scans to capture foveal loss were not used. The majority of the subjects in this study had foveal-involved glaucoma, whereas this information was not available for analysis during our earlier study. Therefore, the differences in results between the studies do not suggest a contradiction, but rather emphasize the differences in the study methodology.

We also observed that a small subset of our glaucoma subjects (7/53 subjects [13%]) with complete MPOD data at all eccentricities exhibited an atypical MP spatial profile,

which peaked at 0.50° of retinal eccentricity. Six of these 7 subjects had foveal-involved glaucoma. In a study of healthy subjects, Kirby et al²⁶ found that atypical MP spatial profile was related to the foveal slope such that the steeper the foveal depression, the steeper the MP distribution. The significance of an atypical MP spatial profile in glaucoma is currently unknown, and therefore further studies are warranted to better understand it.

In this study, both the full parafoveal ($P < 0.001$) and foveal thickness ($P = 0.002$) were significantly lower in the “fovea involved” group, which exhibited greater glaucoma severity. In a study of patients with POAG with isolated superior or inferior hemifield defects, it was shown that the retinal thickness at the parafovea and fovea linearly correlated with glaucoma severity.²⁷ Furthermore, Inuzuka et al²⁷ also showed that the parafoveal and foveal thicknesses were significantly reduced in the corresponding hemifield defects when compared with the normal side. Another study demonstrated the finding of a thin parafoveal ring on time-domain OCT imaging in subjects with more advanced glaucoma but not for full foveal thickness.²⁸ This discrepancy in findings may be related to the use of different OCT imaging modalities across the studies; for example, time-domain OCT has been shown to exhibit a higher percentage of clinically significant inaccurate central foveal thickness compared with FD-OCT.¹⁹

A statistically significantly reduced outer foveal thickness was observed in the “fovea-involved” group ($P = 0.01$). This finding suggests that cone photoreceptors may be affected in foveal-involved glaucoma. A histologic study of human eyes with a diagnosis of chronic glaucoma demonstrated cone photoreceptor swelling and loss.²⁹ Furthermore, fundus reflectometry and OCT imaging techniques have provided evidence of the loss of foveal cone outer segment integrity in subjects with POAG with advanced central visual field

defects,²⁸ while loss of cone density in glaucomatous eyes has been shown to correspond with retinal locations of greater visual sensitivity loss.³⁰ Although this study does not provide definitive evidence of cone photoreceptor loss, the observed involvement of those structures where MP is housed, including significantly thinner parafovea and inner fovea, and a borderline significantly thinner outer fovea, may provide some explanation as to our finding of lower MPOD in foveal-involved glaucoma.

The macula is susceptible to oxidative injury because it is highly aerobic, constantly exposed to light (ultraviolet A and short-wavelength blue light are particularly hazardous), and environmental chemicals such as cigarette smoke.³¹ Furthermore, the presence of high levels of polyunsaturated fatty acids predisposes to the generation of reactive oxygen species. Retinal ganglion cells (RGCs) are highly dependent on mitochondria for energy and are particularly vulnerable to oxidative stress.³² The finding of lipofuscin accumulation in glaucomatous eyes emphasizes the importance of oxidative stress in glaucoma pathogenesis.³³ Ghanem et al³⁴ studied the levels of malondialdehyde, an antioxidant enzyme, in aqueous humor samples of patients with POAG (n = 30) and found that it was significantly correlated with visual field loss ($P < 0.001$), indicating that increased oxidative stress is associated with more glaucoma damage.³⁴ Lutein³⁵ and zeaxanthin³⁶ have been shown to confer a protective effect against oxidative stress-induced cell damage in *in vitro* studies using the RGC-5 cell line. Likewise, lutein has been shown to increase the survival of RGCs by decreasing oxidative stress in a model of acute retinal ischemia—reperfusion in mice.³⁷ We postulate that an environment of high oxidative stress such as glaucoma can cause MP to be depleted, and thereby potentially explain the finding of lower MPOD in glaucomatous eyes exhibiting foveal involvement and more severe damage.

Study Limitations

We were not able to obtain complete MPOD data at all 3 retinal eccentricities in some glaucoma subjects because they found the HFP task somewhat difficult to perform and time-consuming with consequent fatigue. Because the HFP technique is a psychophysical test, it is observer-dependent and may explain the difficulty in carrying out the task. Furthermore, the presence of glaucoma may have contributed to additional challenges. Despite that, HFP is still considered a reliable and practical method to measure MPOD.¹⁶ However, it may be worthwhile to incorporate a less onerous and time-consuming imaging test such as fundus autofluorescence in future studies.^{17,38}

Currently, an imaging system that can accurately measure the GCC thickness at the fovea is lacking. The Cirrus HD-OCT (Carl Zeiss Meditec, Dublin, CA) uses the Ganglion Cell Analysis protocol to measure 2 retinal layers at the macula, namely, the ganglion cell and inner plexiform layers, unlike the RTVue FD-OCT that measures 3 layers including the nerve fiber.³⁹ In the context of studying MP, Cirrus HD-OCT may have a slight advantage over the RTVue FD-OCT because its macular area of analysis is centered on the fovea, compared with 1 mm temporal to the

fovea in the latter. Nevertheless, both OCT devices are not capable of reliably measuring the ganglion cell layer at the fovea. Our method of determining whether GCC loss affects the foveal region by referring to the GCC Significance Map of the RTVue FD-OCT remained effective in providing us with sufficient data for analysis in this study.

Given the limitations of this study, we can only postulate as to the likely explanation for the finding that MPOD is lower in foveal-involved glaucoma. First, as discussed earlier, it may be possible that when the foveal and parafoveal structures are affected in glaucoma, loss of the MP housing initiates MPOD depletion. Second, low levels of MPOD, due to poor dietary intake or impaired carotenoid absorption, metabolism, and transportation, may predispose RGC to oxidative damage because of the lack of its protective antioxidant effect, leading to eventual foveal damage. Third, given that the macula is a highly aerobic tissue and that glaucoma creates an environment of chronic oxidative stress, MP may be constantly used up to scavenge free radicals, leading to MPOD depletion. This may be especially evident in those with foveal-involved glaucoma, in whom the RGCs are under immense oxidative stress and MP storage depletes faster than it can be replenished. Therefore, augmentation of MPOD by dietary modification or supplementation may be desirable in patients with glaucoma, particularly those with evidence of foveal involvement. However, the potential protective role of oral MP supplementation against foveal damage in glaucoma remains to be elucidated.

In this study, we investigated the relationship between MP and macula and optic nerve head topography in glaucoma. Our study complements previous findings that glaucoma is associated with lower MPOD levels and extends the relationship such that MPOD, it seems, is lower in more severe cases of glaucoma exhibiting foveal involvement. Further research is merited to better define the causative roles of oxidative stress, impaired ocular blood flow, and other factors that might influence MP levels in glaucoma. In addition, it is important to evaluate whether oral dietary MP supplementation in patients with glaucoma can (1) increase MPOD and (2) affect glaucoma-related structural parameters.

References

1. Drance SM. The early field defects in glaucoma. *Invest Ophthalmol* 1969;8:84–91.
2. Hood DC, Raza AS, de Moraes CG, et al. Glaucomatous damage of the macula. *Prog Retin Eye Res* 2013;32:1–21.
3. Curcio CA, Allen KA. Topography of ganglion cells in human retina. *J Comp Neurol* 1990;300:5–25.
4. Trieschmann M, van Kuijk FJ, Alexander R, et al. Macular pigment in the human retina: histological evaluation of localization and distribution. *Eye (Lond)* 2008;22:132–7.
5. Bone RA, Landrum JT, Hime GW, et al. Stereochemistry of the human macular carotenoids. *Invest Ophthalmol Vis Sci* 1993;34:2033–40.
6. Khachik F, Bernstein PS, Garland DL. Identification of lutein and zeaxanthin oxidation products in human and monkey retinas. *Invest Ophthalmol Vis Sci* 1997;38:1802–11.

7. Wooten BR, Hammond BR. Macular pigment: influences on visual acuity and visibility. *Prog Retin Eye Res* 2002;21:225–40.
8. Loughman J, Akkali MC, Beatty S, et al. The relationship between macular pigment and visual performance. *Vision Res* 2010;50:1249–56.
9. Bone RA, Landrum JT. Heterochromatic flicker photometry. *Arch Biochem Biophys* 2004;430:137–42.
10. Age-Related Eye Disease Study 2 Research G, Chew EY, Clemons TE, et al. Secondary analyses of the effects of lutein/zeaxanthin on age-related macular degeneration progression: AREDS2 report No. 3. *JAMA Ophthalmol* 2014;132:142–9.
11. Weigert G, Kaya S, Pemp B, et al. Effects of lutein supplementation on macular pigment optical density and visual acuity in patients with age-related macular degeneration. *Invest Ophthalmol Vis Sci* 2011;52:8174–8.
12. Loughman J, Nolan JM, Howard AN, et al. The impact of macular pigment augmentation on visual performance using different carotenoid formulations. *Invest Ophthalmol Vis Sci* 2012;53:7871–80.
13. Tezel G. Oxidative stress in glaucomatous neurodegeneration: mechanisms and consequences. *Prog Retin Eye Res* 2006;25:490–513.
14. Igras E, Loughman J, Ratzlaff M, et al. Evidence of lower macular pigment optical density in chronic open angle glaucoma. *Br J Ophthalmol* 2013;97:994–8.
15. Bone RA, Landrum JT, Cains A. Optical density spectra of the macular pigment in vivo and in vitro. *Vision Res* 1992;32:105–10.
16. Wooten BR, Hammond BR Jr, Land RI, Snodderly DM. A practical method for measuring macular pigment optical density. *Invest Ophthalmol Vis Sci* 1999;40:2481–9.
17. Howells O, Eperjesi F, Bartlett H. Measuring macular pigment optical density in vivo: a review of techniques. *Graefes Arch Clin Exp Ophthalmol* 2011;249:315–47.
18. Stringham JM, Hammond BR, Nolan JM, et al. The utility of using customized heterochromatic flicker photometry (cHFP) to measure macular pigment in patients with age-related macular degeneration. *Exp Eye Res* 2008;87:445–53.
19. Ho J, Sull AC, Vuong LN, et al. Assessment of artifacts and reproducibility across spectral- and time-domain optical coherence tomography devices. *Ophthalmology* 2009;116:1960–70.
20. Bone RA, Landrum JT, Fernandez L, Tarsis SL. Analysis of the macular pigment by HPLC: retinal distribution and age study. *Invest Ophthalmol Vis Sci* 1988;29:843–9.
21. LZQ: Lutein and zeaxanthin questionnaire. Registered Trademark (TXu 1-670-141 effective February 3, 2010): Copyright 2009 Tufts University, Medford, Somerville, Massachusetts.
22. Scanlon G, Connell P, Ratzlaff M, et al. Macular pigment optical density is lower in type 2 diabetes, compared with type 1 diabetes and normal controls. *Retina* 2015 Apr 29 [Epub ahead of print].
23. Beatty S, Murray IJ, Henson DB, et al. Macular pigment and risk for age-related macular degeneration in subjects from a Northern European population. *Invest Ophthalmol Vis Sci* 2001;42:439–46.
24. Hammond BR Jr, Ciulla TA, Snodderly DM. Macular pigment density is reduced in obese subjects. *Invest Ophthalmol Vis Sci* 2002;43:47–50.
25. Tan O, Li G, Lu AT, et al. Mapping of macular substructures with optical coherence tomography for glaucoma diagnosis. *Ophthalmology* 2008;115:949–56.
26. Kirby ML, Galea M, Loane E, et al. Foveal anatomic associations with the secondary peak and the slope of the macular pigment spatial profile. *Invest Ophthalmol Vis Sci* 2009;50:1383–91.
27. Inuzuka H, Kawase K, Sawada A, et al. Macular retinal thickness in glaucoma with superior or inferior visual hemifield defects. *J Glaucoma* 2013;22:60–4.
28. Kanis MJ, Lemij HG, Berendschot TT, et al. Foveal cone photoreceptor involvement in primary open-angle glaucoma. *Graefes Arch Clin Exp Ophthalmol* 2010;248:999–1006.
29. Nork TM, Ver Hoeve JN, Poulsen GL, et al. Swelling and loss of photoreceptors in chronic human and experimental glaucomas. *Arch Ophthalmol* 2000;118:235–45.
30. Choi SS, Zawadzki RJ, Lim MC, et al. Evidence of outer retinal changes in glaucoma patients as revealed by ultrahigh-resolution in vivo retinal imaging. *Br J Ophthalmol* 2011;95:131–41.
31. Beatty S, Koh H, Phil M, et al. The role of oxidative stress in the pathogenesis of age-related macular degeneration. *Surv Ophthalmol* 2000;45:115–34.
32. Chen H, Chan DC. Critical dependence of neurons on mitochondrial dynamics. *Curr Opin Cell Biol* 2006;18:453–9.
33. McElnea EM, Hughes E, McGoldrick A, et al. Lipofuscin accumulation and autophagy in glaucomatous human lamina cribrosa cells. *BMC Ophthalmol* 2014;14:153.
34. Ghanem AA, Arafa LF, El-Baz A. Oxidative stress markers in patients with primary open-angle glaucoma. *Curr Eye Res* 2010;35:295–301.
35. Li SY, Lo AC. Lutein protects RGC-5 cells against hypoxia and oxidative stress. *Int J Mol Sci* 2010;11:2109–17.
36. Nakajima Y, Shimazawa M, Otsubo K, et al. Zeaxanthin, a retinal carotenoid, protects retinal cells against oxidative stress. *Curr Eye Res* 2009;34:311–8.
37. Li SY, Fu ZJ, Ma H, et al. Effect of lutein on retinal neurons and oxidative stress in a model of acute retinal ischemia/reperfusion. *Invest Ophthalmol Vis Sci* 2009;50:836–43.
38. Waldstein SM, Hickey D, Mahmud I, et al. Two-wavelength fundus autofluorescence and macular pigment optical density imaging in diabetic macular oedema. *Eye (Lond)* 2012;26:1078–85.
39. Grewal DS, Tanna AP. Diagnosis of glaucoma and detection of glaucoma progression using spectral domain optical coherence tomography. *Curr Opin Ophthalmol* 2013;24:150–61.

Footnotes and Financial Disclosures

Originally received: April 1, 2015.

Final revision: June 11, 2015.

Accepted: June 17, 2015.

Available online: ■■■■.

Manuscript no. 2015-537

¹ Institute of Ophthalmology, Mater Misericordiae University Hospital, Eccles Street, Dublin, Ireland.

² Optometry Department, School of Physics, College of Sciences and Health, Dublin Institute of Technology, Dublin, Ireland.

³ Faculty of Health Sciences, African Vision Research Institute, University of KwaZulu-Natal, Durban, South Africa.

Financial Disclosure(s):

The author(s) have no proprietary or commercial interest in any materials discussed in this article.

A small funding grant was received from the Howard Foundation to cover the operational costs of running the trial.

Author Contributions:

Conception and design: Siah, Loughman, O'Brien

Data collection: Siah

Analysis and interpretation: Siah, Loughman, O'Brien

Obtained funding: Not applicable

Overall responsibility: Siah, Loughman, O'Brien

Abbreviations and Acronyms:

AMD = age-related macular degeneration; **ANOVA** = analysis of variance; **EMM5** = Enhanced Macular Map 5; **ETDRS** = Early Treatment Diabetic Retinopathy Study; **FD** = Fourier domain; **GCC** = ganglion cell

complex; **HFP** = heterochromatic flicker photometry; **HVF** = Humphrey visual field; **logMAR** = logarithm of the minimum angle of resolution; **MD** = mean deviation; **MP** = macular pigment; **MPOD** = macular pigment optical density; **NTG** = normal-tension glaucoma; **OCT** = optical coherence tomography; **POAG** = primary open-angle glaucoma; **RGC** = retinal ganglion cell; **RNFL** = retinal nerve fiber layer.

Correspondence:

We Fong Siah, MRCPI, FRCOphth, Institute of Ophthalmology, Mater Misericordiae University Hospital, Eccles Street, Dublin 7, Ireland. E-mail: wefong_siah@yahoo.com.